

MICROINSTABILITY OF THE HIP: A NEW CONCEPT TO EXPLAIN UNCLEAR HIP AND GROIN PAIN

<https://doi.org/10.71165/adar-07ia>

AUTHOR

Frédéric Laude - Clinique du Sport, Paris, France

SUMMARY

Background: Symptomatic hip microinstability is an increasingly recognized cause of chronic pain and functional impairment, yet it frequently remains underdiagnosed. While femoroacetabular impingement is well-documented, microinstability—defined as extraphysiologic femoral head motion—presents a distinct pathology involving osseous morphology and capsulolabral integrity.

Objective: This review aims to define the etiology of hip microinstability, establish standardized clinical and radiographic diagnostic criteria, and evaluate current conservative and surgical management strategies.

Key Points: Pathogenesis is often multifactorial, involving acetabular dysplasia, femoral malrotation, connective tissue laxity, or iatrogenic capsular insufficiency. Clinical diagnosis relies on provocative maneuvers, including the anterior apprehension, prone external rotation, and FABER tests. Radiographic assessment utilizes the lateral center-edge angle, the femoro-epiphyseal acetabular roof (FEAR) index, and the "cliff sign." Management begins with conservative protocols focusing on periarticular muscle strengthening. For refractory cases, surgical intervention targets the specific pathology. Arthroscopic techniques include labral repair and capsular plication to restore joint tension. In cases of significant osseous deficiency, periacetabular osteotomy (PAO) or femoral derotation osteotomy is indicated to optimize joint coverage and alignment. Minimally invasive PAO techniques have reduced recovery times while maintaining clinical efficacy.

Conclusion: Accurate diagnosis of hip microinstability requires clinical suspicion and comprehensive imaging. Treatment should be individualized, progressing from conservative rehabilitation to targeted surgical stabilization of soft tissues or osseous structures to prevent joint degeneration.

KEYWORDS

Joint Instability; Hip Joint; Arthroscopy; Osteotomy; Acetabulum

Symptomatic hip microinstability is very often not diagnosed. It has been identified recently as a potential cause of chronic pain and disability. Clinical and imaging diagnosis is helpful to identify this new pathology. Non-surgical management should be the first choice and surgical intervention might be considered in patients with persistent pain.

INTRODUCTION

For the past twenty years or so, hip specialists have been studying the concept of femoroacetabular impingement. This has improved their understanding of the pathogenesis of osteoarthritis of the hip, and some cases are now even suitable for surgical correction (1-4). However, even if there is a lack of any radiograph findings, not all incidences of hip pain are due to impingement. Influenced by the two American surgeons Marc Safran (5, 6) and Marc Philippon (7), we are beginning to better understand the concept of microinstability and new treatments are being developed, both conservative and arthroscopic. Hip instability is a somewhat vague term. The hip obviously obtains much of its natural stability from the skeletal anatomy, with a femoral head designed to sit neatly inside the bony acetabulum, but the adjacent soft tissues also contribute to the stability. The acetabular labrum and the up to a centimetre thick joint capsule are surrounded by 17 of the body's most powerful muscles. So how can such a well-designed joint become unstable?

We are all familiar with hip dysplasia, a condition studied at length by Michel Lequesne (8) and many others. The most severe form of dysplasia is high dislocation of the hip. Although congenital hip dysplasia has now virtually disappeared from practice, there are still numerous cases where the bony acetabulum is not severe hypoplastic and looks quite normal orientated, but is nevertheless causing clinically relevant hip instability. Over one third of adulthood cases of osteoarthritis of the hip are caused by these small coverage defects, which gradually lead to anterior subluxation of the femoral head and destruction of the joint (9). This particular condition is well-defined, but painful hips can sometimes also be explained by damage to the soft tissues surrounding the joint, especially the capsular-labrum complex.

This often reveals itself in patient who have had an arthroscopy for a torn labrum with or without refixation. During the procedure the capsule has been left open or resected, which then might start to develop new pain that is sometimes more disabling than before the surgery. A similar situation has been described in cases of recurring dislocation after arthroscopy of the hip (10). Another extreme example is patients with Ehlers Danlos Syndrome, which is characterised by pathological capsular laxity (11, 12) but normal bony structure, who can suffer severe instability which is both painful and hard to treat. These situations have revealed a growing need for us to define a new pathological entity, namely microinstability of the hip.

Definition

Microinstability of the hip is defined as extraphysiologic hip motion that damages the labrum and adjacent cartilage and can cause pain and ultimately destruction of the joint. This microinstability may be due to bony deficiency or soft tissue damage or loss around the hip joint. It should not be confused with femoroacetabular impingement as although the two conditions often coexist. With an impingement, the damage is caused by abnormal shaped femoral head and neck (cam impingement) or overcoverage of the acetabulum or retroversion of the acetabulum (pincer impingement). Both during flexion place excessive localized pressure on the acetabular rim, resulting in damage to the labrum and the adjacent cartilage. With instability, the head of femur subluxes outwards when the joint is extended and causes damage, which is in fact very similar to that caused by impingement (Fig. 1).

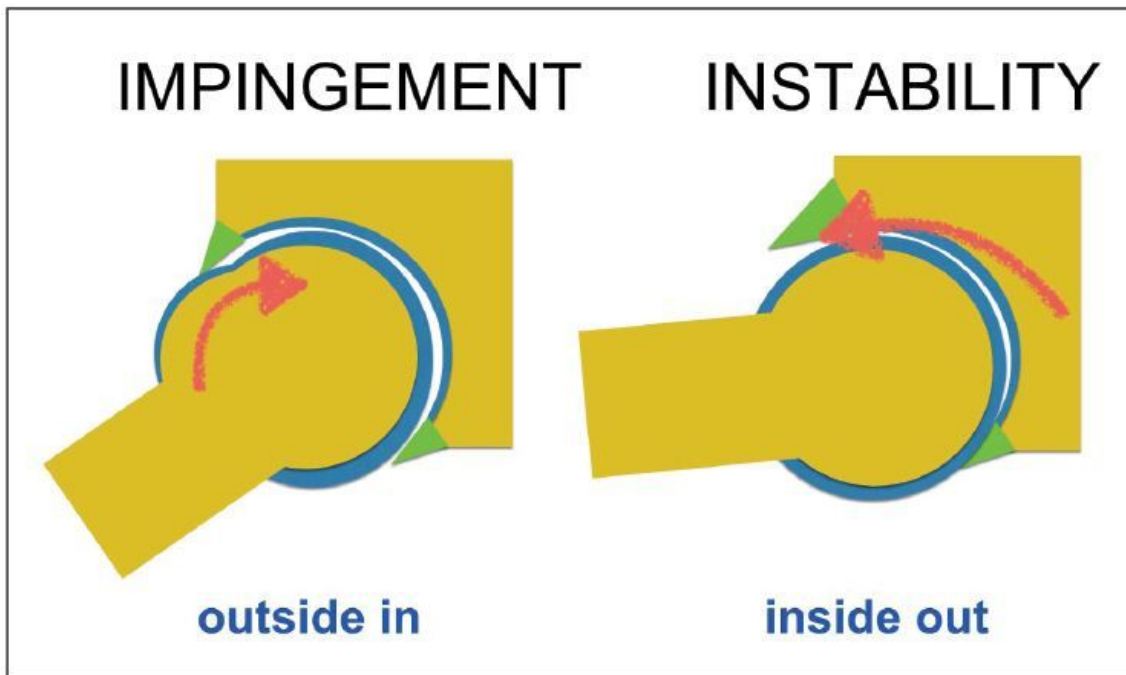


Figure 1: Basic difference between instability and femoroacetabular impingement. With impingement, the damage occurs during flexion of the hip when the ‘cam’ pokes into the joint. With instability, the damage occurs mainly during extension when the head subluxes forward. A physical examination for instability therefore should check for pain in extension and external rotation.

HIP STABILITY

Bones

The acetabulum is almost an entire hemisphere that covers the head of femur. Around the rim is the labrum, formerly known as the cotyloid ligament, a soft fibro-cartilaginous structure that increases the size of the acetabulum by nearly 20% and the contact surface by 25% (13, 14). It keeps the fluid inside the joint at negative pressure, which is clearly felt when performing an arthroscopy. When placed in traction, the joint initially resists then suddenly gives way to allow the cavity to be opened and accessed (central compartment). The labrum therefore plays a crucial role in joint stability. The acetabulum covers the femoral head by 45° lateral tilt and 15 to 20° of anteversion. Acetabular anteversion is a complicated concept because the upper part of the joint is often in retroversion (overhanging wall creating a risk of impingement in flexion) whereas the lower portion clearly faces forward. The femoral neck is set at an average angle of 130° from the diaphysis and posterior femoral condyles, but it also usually faces forward at an angle of 5–25° antetorsion. Above 30° is classed as pathological antetorsion. As the body grows, this angle reduces before settling at its final size. Too much femur antetorsion and/or coxa valga can promote instability and damage the anterior acetabular wall. The combination of excessive femur antetorsion and insufficient anterior coverage of the acetabulum is very common. The femur torsion and acetabulum version show a complex relationship to each other and can either compensate or make instability even worse. This complex relationship can be defined by the McKibbin Index of the hip joint (Fig 2).

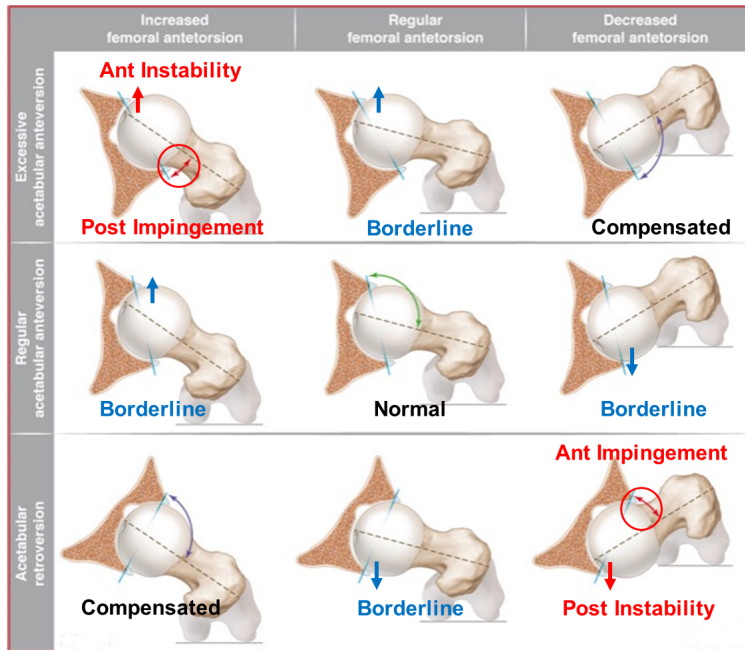


Figure 2: McKibbin Index Shows acetabular version (solid line) and femoral torsion (dotted line). Depending on the relationship of version and torsion there is an increased or borderline risk for anterior or posterior instability and opposite impingement.

Joint capsule (Fig. 3)

The hip has the most solid joint capsule in the entire body. It has four ligaments, each of which stabilize the joint in different positions. These three ligaments wrap around the femoral neck and give the capsule a spiral shape which tightens in extension, encourages the circulation of synovial fluid into the cavity, and creates natural fixation of the joint (15, 16). When examining a patient for instability, the hip should be placed in extension.

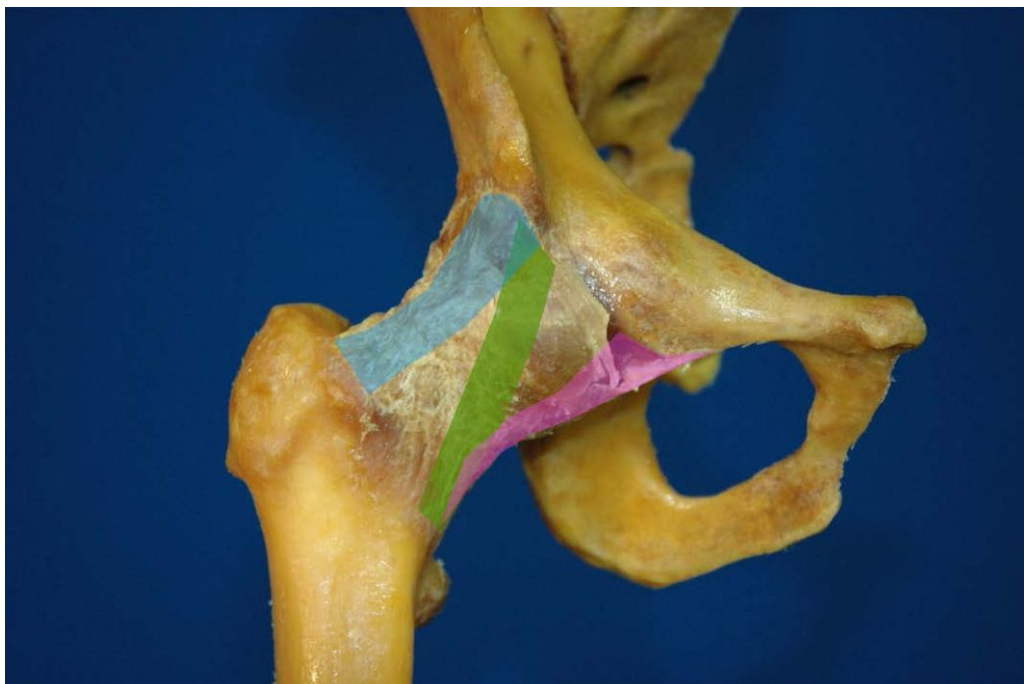


Figure 3: Anterior capsule ligaments: the two bundles of the iliofemoral ligament are shown in green and blue. These are the strongest ligaments in the body. They can be up to 1cm thick. The pubofemoral ligament is in pink.

The iliofemoral ligament or (Y ligament) is the strongest in the body. Its upper fibres arise from the anterior inferior iliac spine just beneath the origin of the rectus femoris tendon. The lateral band attaches in front of the greater trochanter onto the trochanteric tubercle. The medial band wraps around the femoral neck and attaches just above the lesser trochanter. Its role is to restrict external rotation of the hip in flexion. When the hip is extended, it restricts external and internal rotation. The lower portion of the ligament just above the calcar and lesser trochanter merge with the fibres of the medial located pubofemoral ligament. The pubofemoral ligament originates from the anterior inferior acetabulum. Its main role is to restrict external rotation of the hip in extension. The ischiofemoral ligament starts at the ischial acetabular margin and wraps around the femoral neck behind the joint. Its role is to limit posterior translation and internal rotation in both flexion and extension (17). The zona orbicularis is a capsular thickening encircling the femoral neck and limits femoral head distraction.

The ligamentum teres (LT) origin from the transverse acetabular ligament and attaches to fovea capitis femoris. It tenses in flexion, adduction and external rotation. If torn, patients can experience discomfort or a snapping movement in the joint. This is an excellent sign of instability. Obviously, the head of femur does not always stay at the exact centre of rotation of the acetabulum. There may be natural displacement of up to 4 mm, and posterior disengagement is commonly seen in dancers when at maximum flexion (18, 19). Although there may be relative movement of the femoral head inside the bony acetabulum, the role of the capsule is to limit and restrict movement in order to avoid extreme joint positions that can cause destructive impingement between the head and neck of femur and the labrum. Excessive participation in sports will ultimately cause damage and stretch the capsule, causing labral tears which will in turn worsen the instability, placing the joint into a vicious cycle of destruction.

The muscles obviously also have a role to play in stabilizing the joint. Especially the small iliocapsularis muscle plays an important role to stabilize the hip and is often hypertrophied in cases of unstable dysplasia of the hip (20).

AETIOLOGY

There are numerous factors, at least five, that can cause microinstability of the hip, which may occur in isolation or be combined. In most cases this is therefore a multifactorial condition (6).

1. Bone pathology: Insufficient anterior and/or lateral acetabular coverage, excessive acetabular anteversion, excessive femoral antetorsion.
2. Connective tissue disorders: Ehlers Danlos, Marfan and Down syndromes (see fig 4 Beighton score)
3. Microtraumatic (sports involving wide ranges of motion)
4. Post traumatic
5. Iatrogenic damage (arthroscopy of the hip with partial resection of the capsule).

Anterior subluxation of the femoral head can, for example, damage the anterior capsule which in turn increases the subluxation, leading to labral damage which worsens the instability. If a high-risk sports are performed, this can very often result in highly painful microinstability in patients not yet out of their teens.

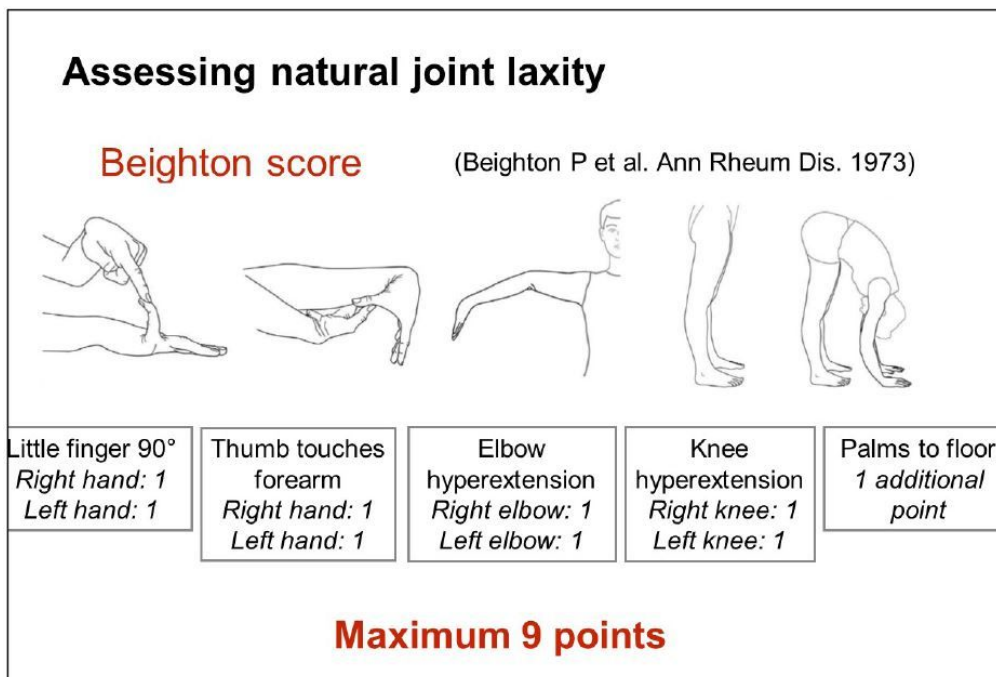


Figure 4: Beighton score describes five tests to identify pathological soft tissue laxity

The instability may also be accompanied by femoroacetabular impingement. Some authors have described posterior subluxation during weight-bearing flexion. The head–neck junction rests on the anterior acetabular rim and stretches the capsule, leading also to problems of microinstability (21). More recently, there have been reports of recurring dislocation of the hip following arthroscopic surgery.

Aggressive opening of the capsule and especially the iliofemoral ligament in order to expose the acetabulum can encourage subluxation and even recurring anterior dislocation. Systematically closing the capsule, even in cases of isolated impingement, gives better outcomes even for hips that are not particularly lax and hard to distract (22).

CLINICAL DIAGNOSIS

If there is one condition particularly prone to diagnostic delay, it is microinstability of the hip. Since it is usually multifactorial, it is not always easy to identify the individual triggers. Doctors like things to be clear, easy to identify and prefer if one obvious cause leads to the problem. For example, Mycobacterium tuberculosis causes tuberculosis; traumatic tear of the anterior cruciate ligament leads to instability of the knee etc. We treat the cause, and the problem is supposed to disappear, or at the very least improve!

With microinstability, having just one causative trigger is the exception rather than the rule. There may be a combination of slight loss of anterior acetabular coverage (acetabular anteversion) which is nearly invisible to the uneducated eye on frontal pelvic x-rays, borderline laxity of the legs which was not screened for, a history of competitive gymnastics 10 years ago, some recent slight muscle atrophy, or a labral tear invisible on the pelvic MRI (poorly executed or misinterpreted). Together, these multiple factors will ultimately cause intense pain, but without anyone suspecting microrinstability of the hip with subluxation under the slightest pressure. Most patients complain of pain deep to the hip joint (C-sign) or deep groin pain, which is aggravated by rotational activities under load or with hyperextension. Think twice before rushing to order radiological tests, most of which are static (including ultrasound). A physical examination is the best way forward, and we need to restore its former glory.

It is important to note that the condition mostly affects young women with hypermobility of the joints. They may have participated in a sport as a teenager that required a wide range of joint motion. Patients certainly never use the words 'dislocated' or 'dislocation' when describing their hip, as they would with a shoulder. They usually describe a gradual onset of pain, and a clunky or snapping joint. Another very good sign is pain when the patient places weight back onto the body, moving the joint from flexion to extension (e.g. getting up from a chair). It is not unusual for the patient to place their hand over the groin fold, instinctively exerting pressure to stabilize the hip. Pain in the buttocks due to overuse of the gluteal muscles is common. Patients are often quite worried and frustrated, because it has taken months or maybe years to find a diagnosis. Worse, to protect their hip especially in cases of deficient anterior coverage, patients tend to adopt a hyperlordotic posture (protectively tilting the pelvis to increase anterior acetabular coverage), which will ultimately lead to lumbar pain. A history of lumbar surgery is unfortunately not uncommon. But it will obviously not have solved the problem.

The physical examination should try to reproduce the problems described by the patient. Both external internal rotation should be assessed with the patient in prone position and the knees flexed to 90°. If the angle of internal rotation is greater than the angle of external rotation, then it is highly likely to be a case of excessive antetorsion of the femoral neck. External rotation greater than 60° is also a very good sign of laxity.

Marc Safran recommends six laxity tests: (6) (Figs. 5-10)

1. Anterior apprehension test (sensitivity 71%, specificity 85%)
2. Abduction, extension and external rotation (sensitivity 81%, specificity 89%)
3. Prone external rotation test (sensitivity 33% but specificity 98%)
4. Leg roll test
5. Axial distraction test
6. Posterior apprehension test

If the first three tests are positive, the diagnosis of microinstability is 95% reliable.

Figure 5: Anterior extension (Heer) test. The patient lies supine, on the end of the table. The knee is flexed. The leg being tested is placed in hyper extension, and the examiner applies external rotation, placing pressure on the labrum and the anterior capsule to recreate the discomfort described by the patient. Any posterior pain is explained by a posterior impingement.

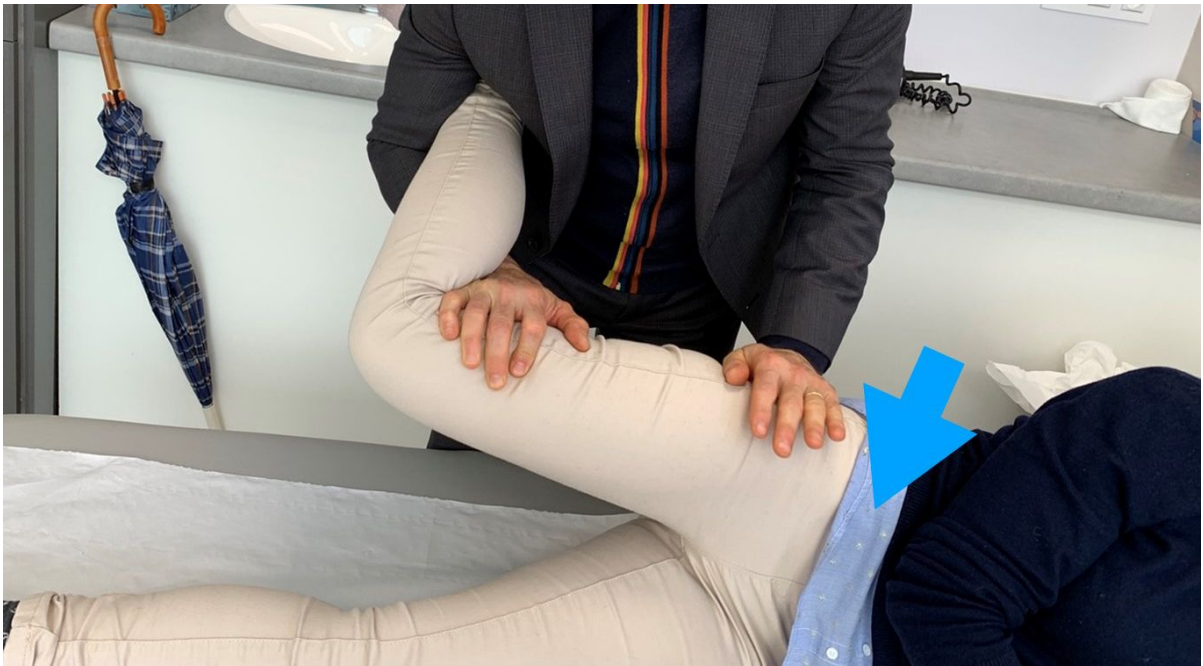

Figure 6: Abduction, extension and external rotation test. The patient is placed in lateral decubitus. The thigh is abducted to 30°, the lower leg is placed in external rotation, and the examiner presses forward on the back of the greater trochanter. This should reproduce the patient's pain.

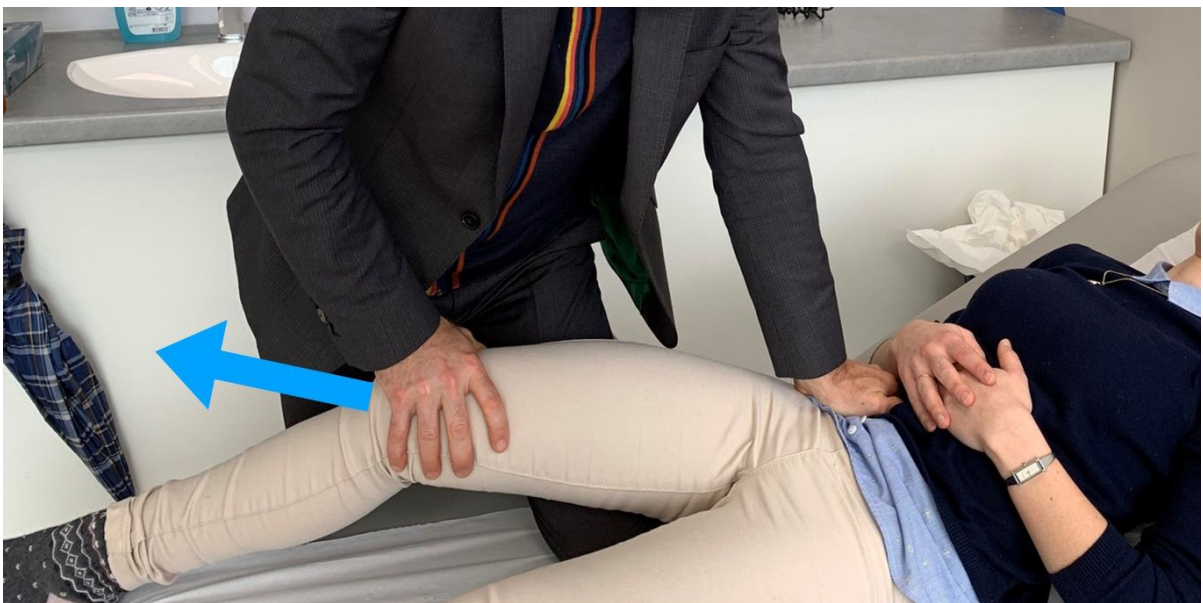

Figure 7: Axial distraction test The patient lies supine. The examiner places his knee on the ischium. The knee and hip are flexed to 30°. The examiner places traction on the leg by pressing down the knee in order to recreate the instability or pain familiar to the patient.

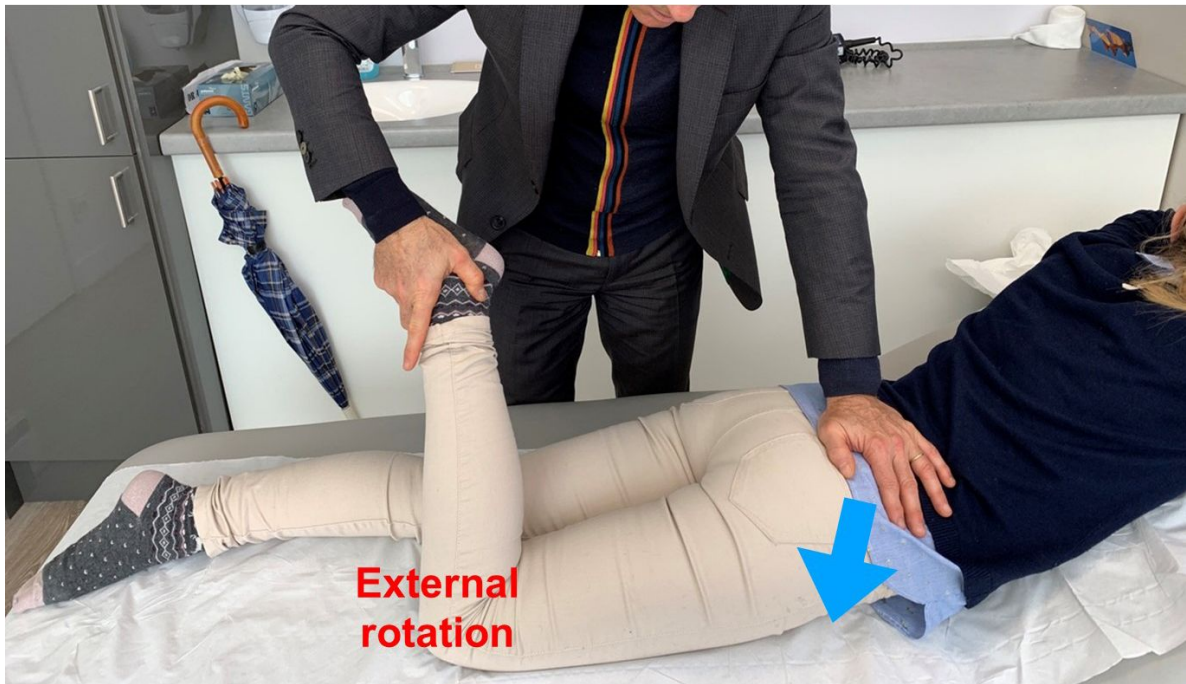

Figure 8: Prone external rotation test. The patient lies on the stomach. The hip is placed in external rotation and the examiner pushes on the posterior aspect of the greater trochanter.

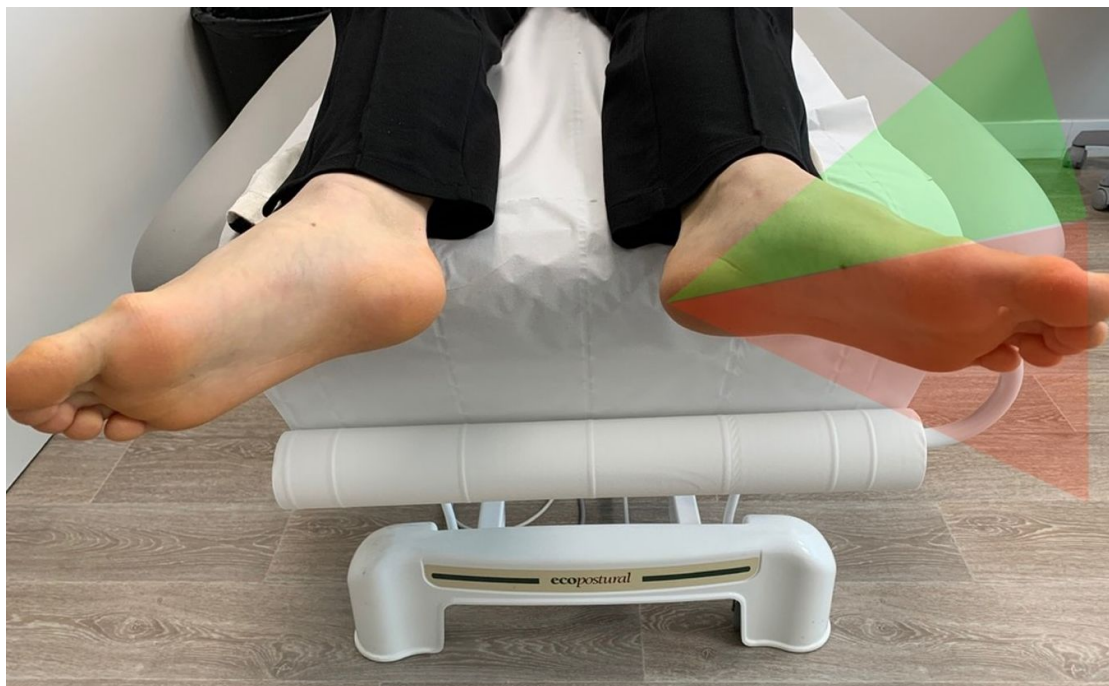

Figure 9: Leg roll test: The patient lies supine, the legs extended. With the patient relaxed, the examiner places both feet in maximum external rotation then suddenly releases them. The side with greater laxity will exhibit greater external rotation. A foot that spontaneously lies at an angle of less than 20° from the tabletop represents a sign of laxity.

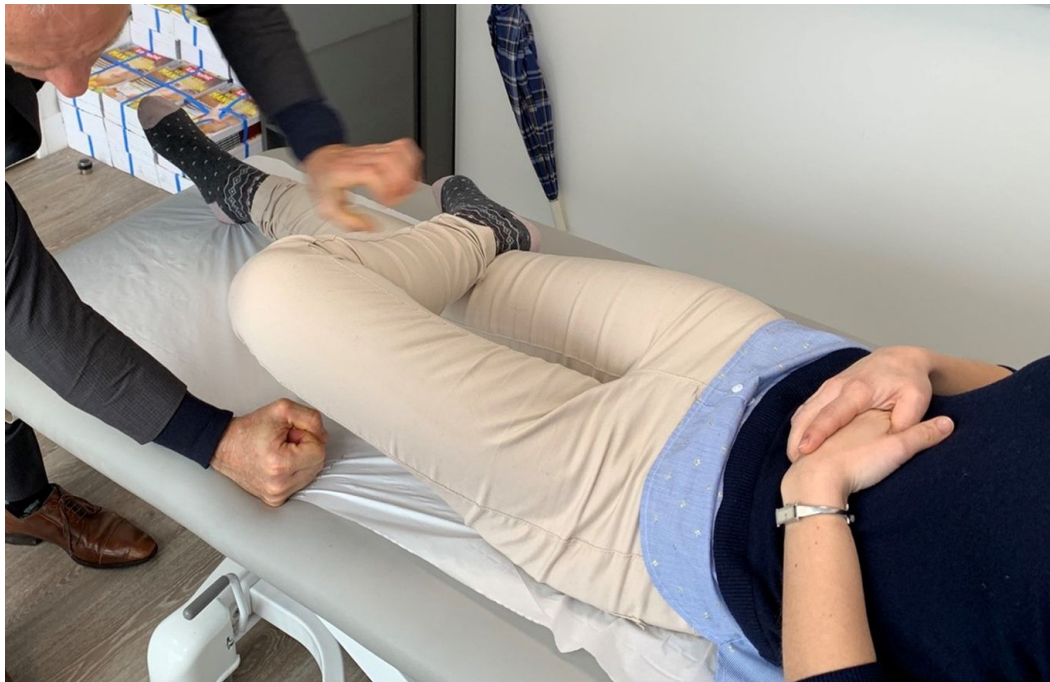

Figure 10: FABER test. Flexion Abduction External Rotation. The patient lies supine. The foot is placed on the opposite knee. The distance between the knee and the tabletop gives a good indication of laxity (or stiffness). The examiner should use his fist as a gauge of minimum distance. If the knee touches the fist, or worse, the table, the sign is positive for laxity.

Patients very often complain of an audible snap during active or passive mobilization of the joint. This idea of a ‘snap’ is very often misinterpreted, and many practitioners diagnose this as coxa saltans or snapping psoas. Any snap during active or passive mobilization of the hip should be considered as coming from inside the joint, until proven otherwise! In the vast majority of cases, the problem is due to a band of cartilage 5–10 mm wide just behind the labrum. During arthroscopy it shows a soft cartilage that has doubled in volume, to the point it gets caught on the rim of the femoral head, causing this audible snap. Ultrasound, being the only dynamic test, which might be helpful. The Beighton score (Fig. 4) can also be used to check for general hypermobility. Although not perfect, this test is important because the treatment will be different for a hyperlaxed person and for the average person. When it comes to treatment, the test clearly has a part in the decision-making process.

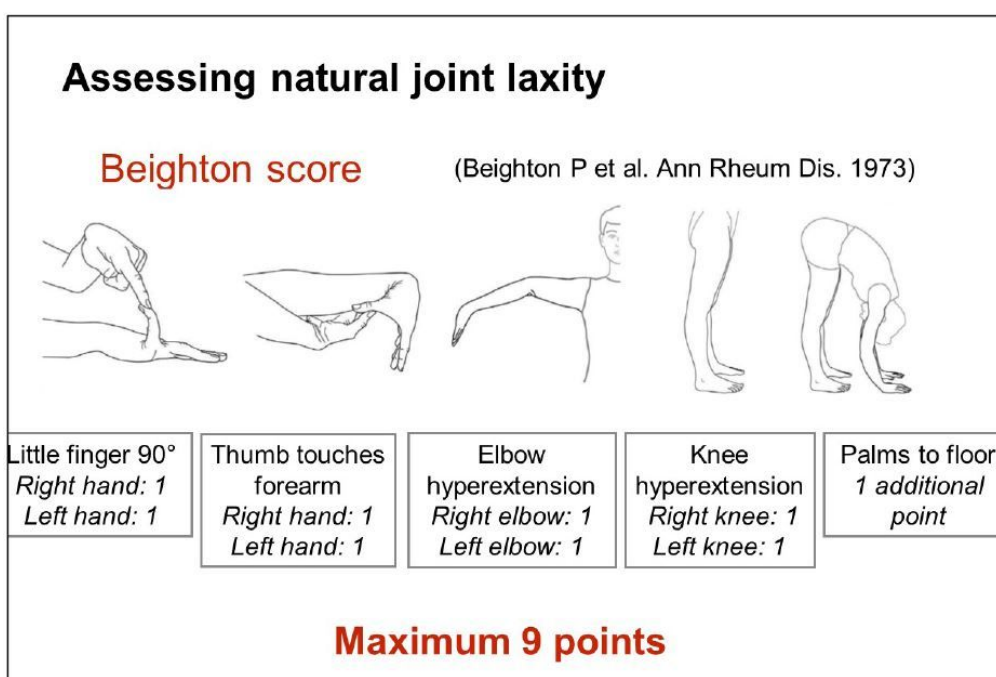


Figure 4: Beighton score describes five tests to identify pathological soft tissue laxity

IMAGING DIAGNOSIS

One can never overestimate the benefits of good standard x-rays and the misery that can be caused by sophisticated but badly performed or misinterpreted tests (CT scans and MRI). The only way to get a perfect assessment is from an expert radiologist working in conjunction with one of the rare orthopaedic surgeons with an interest in this topic (23-25). The first standard x-rays should be standing frontal pelvic views, a Lequesne's false profile and a Dunn view to assess any accompanying femoroacetabular impingement. The frontal pelvic and false profile views are used to calculate acetabular coverage and identify dysplasia. Coverage less than VCE 25° is suspicious, and an angle of less than 20° as well as an acetabular roof angle > 10° are frankly concerning because it often means that the acetabular bony coverage or position will have to be corrected (Fig. 11). A blunt acetabular rim is also highly suggestive of instability.

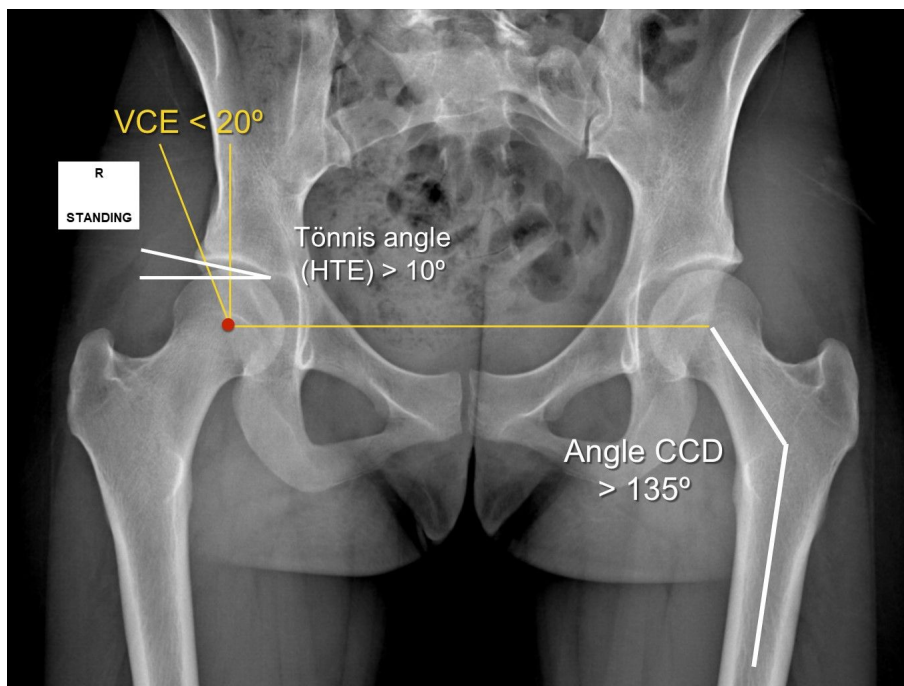


Figure 11: The three basic radiographic angles. LCEA (Lateral Center Edge Angle or VCE): should be higher than 28°. ARA (Acetabular Roof Angle or acetabular index or Tönnis angle HTE) should be lower than 10°. CCD (caput-column-diaphyseal angle): less than 135°.

It is also important to learn how to assess the anterior and posterior walls on frontal pelvic x-rays, and not just stick to the standard measurements (Fig. 13).

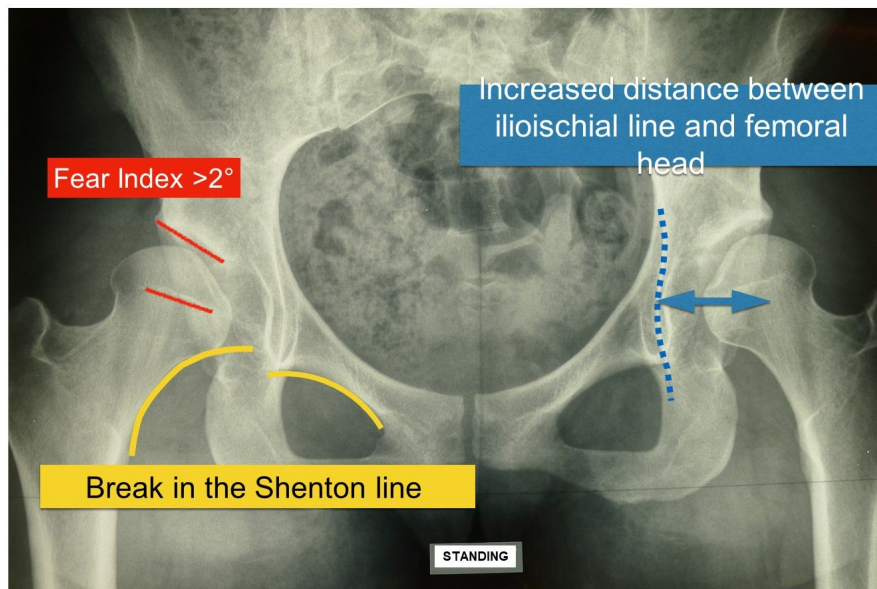


Figure 13: Three Radiological signs for instability of the hip. FEAR Index, Break of Shenton line and increased distance of ilioischial line and femoral head

Very close attention should be paid to the so called “cross-over-sign”. The anterior wall should sit in the middle third of the gap between the centre of the head and the fovea. The posterior wall should pass by the mid third of the femoral head (Figs. 16 and 17).

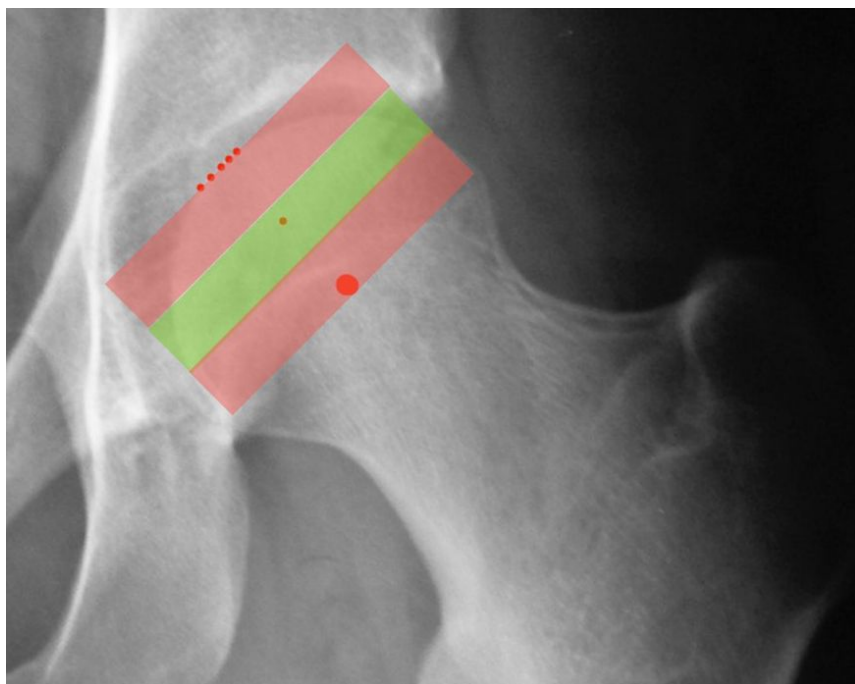


Figure 16: The anterior acetabular wall should be located in the mid third of the space between the centre of the femoral head and its medialmost part. If the wall is in the medial third, the anterior wall does not offer full coverage and is less effective. If it is in the lateral third, there is most likely retroversion and pincer impingement (excessive wall coverage).

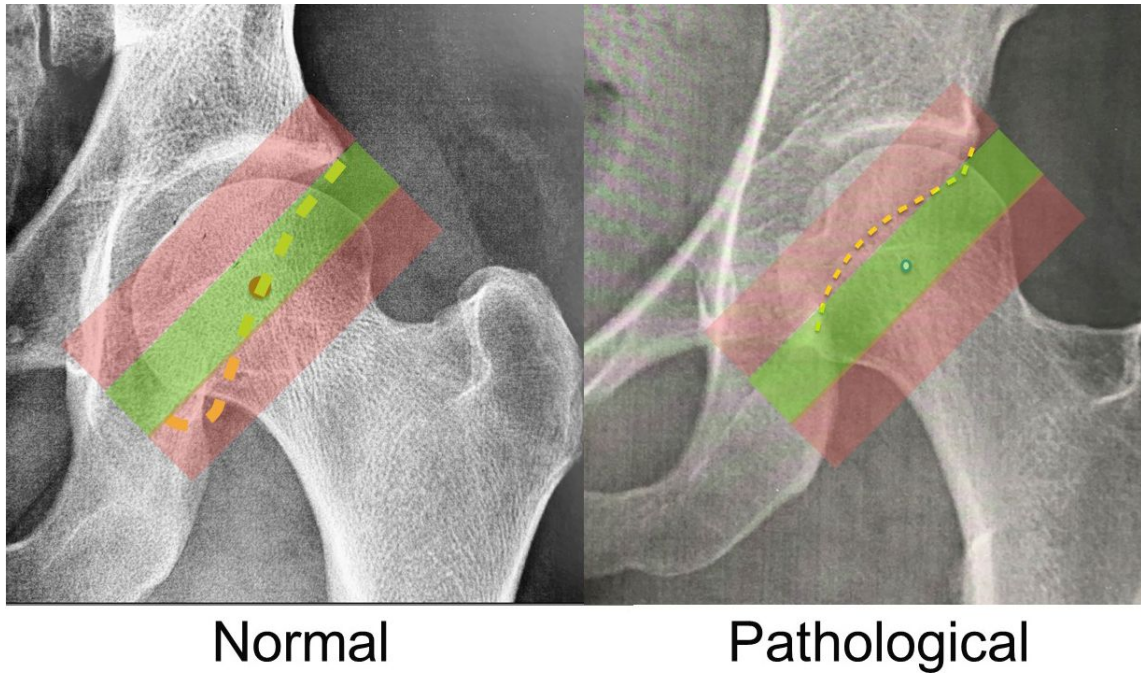


Figure 17: The posterior acetabular wall crosses the centre of the femoral head. If this line is in the lateral third the acetabulum is too much anteverted and if its medial retroverted. Acetabular version can be determined by examining the two walls on frontal views and the “Cross over sign” represents also an indicator for too much acetabular anteversion.

Furthermore, acetabular retroversion can be identified by the posterior wall and/or ischial spine sign. Dunn views should be used to check for any bump that could cause cam impingement. The alpha angle (29) (Fig. 14) should be calculated, and the head–neck junction checked for cysts or any signs of sclerosis.

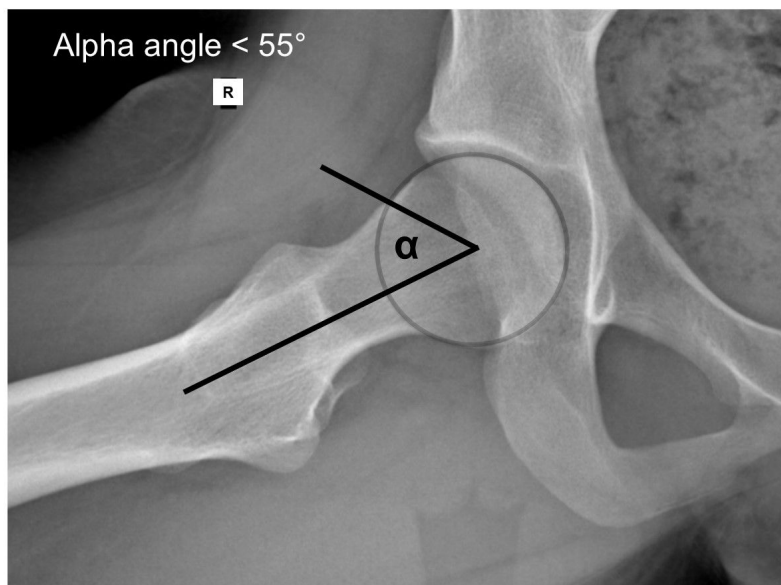


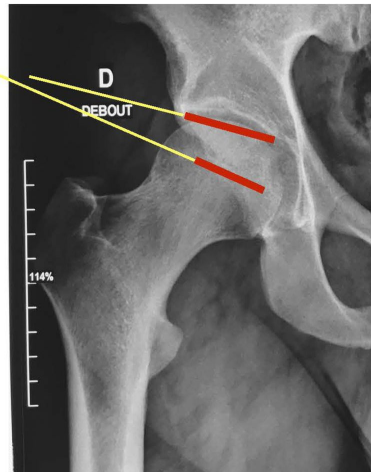
Figure 14: Alpha angle is calculated between a line extending to the centre of the femoral head from the femoral neck, and a second line connecting the point of loss of sphericity of the femoral head to the centre of the femoral head. This angle can be calculated in all projections on scan images, but the easiest way is to use Dunn views.

Martin Beck (26) has recently described another excellent sign of instability, known as the FEAR index (Femoro Epiphyseal Acetabular Roof) which is the angle between the acetabular sourcil and the femoral head physeal scar (Fig. 12).

Femoral-Epiphyseal Acetabular Roof (FEAR) index $> 2^\circ$

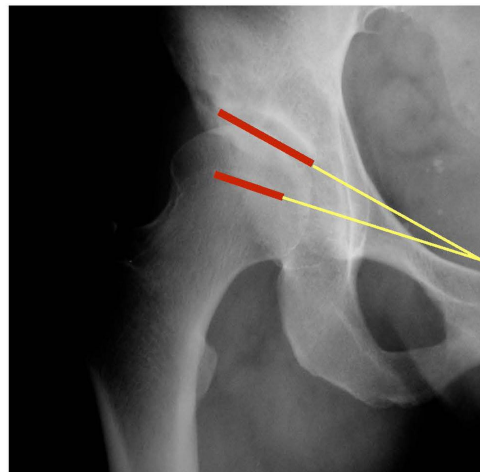
Wyatt M et al. CORR 2017

Fear index = -5° donc négatif



Stable

Fear index = $+4^\circ$ donc positif



Instable

Figure 12: FEAR index (Femoral-Epiphyseal Acetabular Roof): the upper line follows the acetabular sourcil. The lower line lies along the trajectory of the central portion of the physeal scar of the femoral head. If the two lines meet towards the inside of the pelvis (plus degrees), the hip is unstable. If the two lines meet outside the pelvis (negative degrees) there are no signs of instability.

The idea came from the fact that during adolescence, the epiphyseal growth plate of the femur orients itself perpendicularly to the forces applied to it, and thus to the acetabulum. If the hip is unstable and subluxes, the growth plate is no longer parallel to the roof of the acetabulum. A recent study has validated this radiological sign in a group of 150 patients undergoing arthroscopy. The FEAR index was significantly more positive in the unstable hips compared with the stable ones (27). Finally, another excellent sign to be aware of, again described by Marc Safran, is the Cliff Sign (28). An unstable hip will nearly always have a very narrow neck and a head that is no longer a perfect circle, losing some sphericity where it 'exits' the acetabulum i.e. around its lateral aspect (Fig. 15). The larger the lateral empty space, the greater the sign.

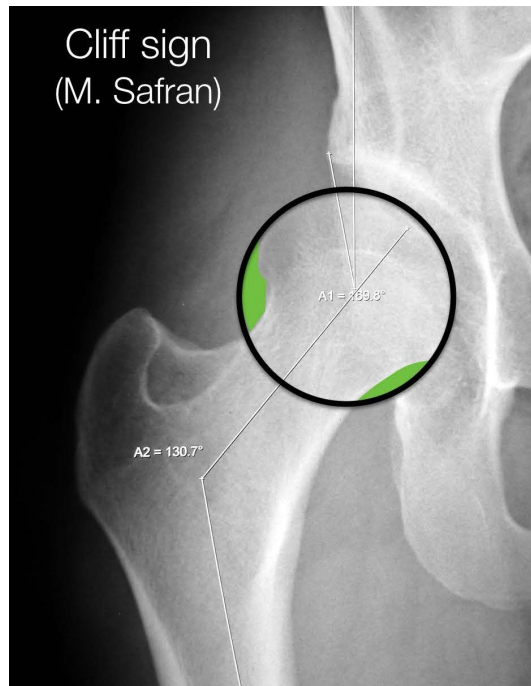

Figure 15: Cliff sign. Unstable hips very often have a loss of sphericity on the lateral femoral head. Simply draw a circle of the femoral head, and assess the size of the gap on the lateral aspect (in green). An unstable hip also has a narrow neck and a high head–neck ratio.

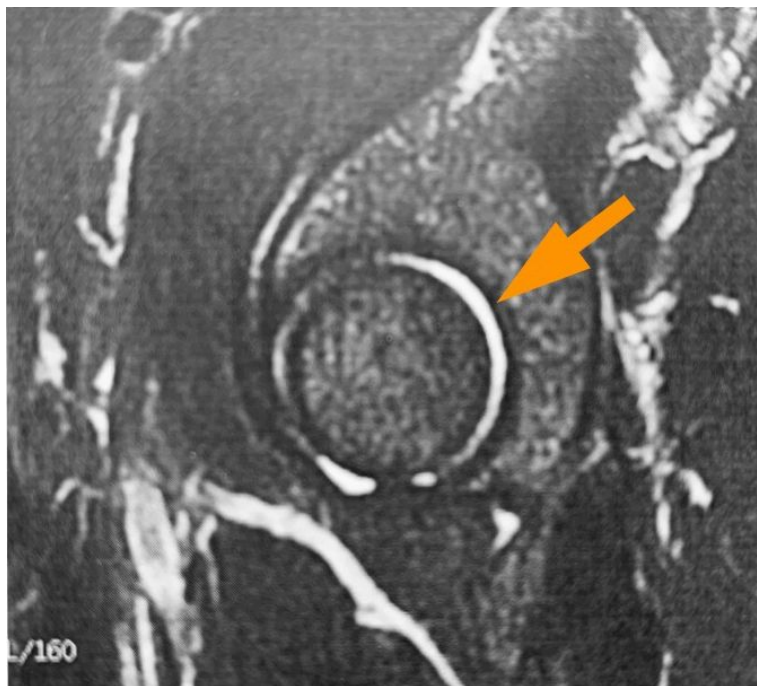

Figure 18: In MRI images for microinstability, check for an overfull capsule with an anterior recess greater than 5 mm, a thin capsule (<3mm) and a posterior crescent sign in at least two views.

Basics CT scans are no longer of much use, except for surgeons. 3D models can help plan bone reconstructions, if necessary. Only special performed high resolution MRI images in the coronary, axial, sagittal and radial planes are sensitive enough and useful (30). A simple MRI of the pelvis will risk completely overlooking the problem and, in the worst-case scenario, send the patient home with a diagnosis of a normal hip. The MRI scan of the hip must therefore be conducted using special protocols that very few centres have as a routine.

It is often easier to order an arthrography, possibly with injection of an anti-inflammatory. Examinations using intra-articular contrast material (CT scan or MRI) reveal a thin-walled capsule, which readily takes up lots of

contrast, and a distinct crescent sign with collection of fluid at the posterior joint indicating anterior subluxation (Fig. 1). If the patient has already undergone arthroscopy of the hip, there may be residual signs of the surgery. The labrum and cartilage must be examined carefully, but it should be noted that labral damage can be easily missed or underestimated by an arthrogram. Specificity can be improved by placing the hips under traction during the procedure, but this is never actually done, even when requested (30).

With all these clinical and imaging tests, practitioners should be able to diagnose microinstability of the hip. This is probably an area in which artificial intelligence would help, because the symptoms are broad, varied and numerous. There is no one particular sign to look for, and for the time being the decision will depend on clinical experience (Figs. 19–20).

Radiological evidence of hip instability

| | Predictive value |
|---|------------------|
| Break in the Shenton line | 100% |
| Increase in distance from femur to ilioischial line | 100% |
| Abduction recentres the femoral head | 100% |
| Posterior disengagement on MR arthrogram | 90% |
| Fear Index >2° | 92% |

Wyatt M, Beck M. JHPS 2018

Figures 19–20: Imaging Evidence and Probability of Instability signs by using radiographs and MR-imaging

Radiological indications of probable hip instability

| | Predictive value |
|---|------------------|
| VCE (Wiberg's angle) <20° | 70% |
| HTE (Tönnis angle) > 10° | 70% |
| CCD (caput-collum-diaphyseal angle) >135° | 55% |
| Femoral anteversion >25° | 70% |
| Hypertrophic labrum | 50% |
| Hypertrophic iliocapsularis muscle | 50% |
| Round ligament tear | 70% |

Wyatt M, Beck M. JHPS 2018

Figures 19–20: Imaging Evidence and Probability of Instability signs by using radiographs and MR-imaging

TREATMENT OPTIONS

As always with most chronic orthopaedic conditions, surgery is only considered once the limits of extensive conservative treatment have been reached. This should be designed to improve stability of the hip by adapting the patient's daily activities and sports, strengthen the muscles around the joint and work on proprioception (31-34). If conservative treatment does not provide satisfactory, long-lasting improvement, surgery should be discussed. The surgeon has two possible targets: the soft tissues and the bones.

Soft tissue surgery

This is nowadays almost entirely arthroscopic. The procedure takes place in three stages.

The first stage includes the placement on the traction table and distraction of the hip joint to confirm the instability. These hips are very easy to distract and it is not unusual to be able to enter the central compartment without even having to place the hip under traction. The anaesthesia alone is enough to open the joint, which is quite unusual for the hip.

The second stage involves a comprehensive assessment of all joint damage, then repairing or reconstructing the labrum. As we have seen, the labrum accounts for around 20% of joint stability and is also a highly innervated region. It is essential to check the condition of the cartilage. Apart from subchondral bone drilling (as described by Pridie) or microfracturing (35) there is no truly effective solution for damage to the acetabular cartilage. Small isolated lesions on the head of femur do however respond very well to the mosaicplasty technique (36). Very often there is an anterior lateral band of chondromalacia causing the snap described by so many patients (Fig. 20). Unfortunately, not much can be done with this cartilage, but repairing the labrum and reducing the instability will almost always solve the problem. If the labrum cannot be repaired, it can be attached to the acetabular wall following a minor acetabuloplasty. Some authors suggest reconstruction using either a band of fascia lata, a hamstring tendon or an allograft (37). The femoral head should be inspected, and you will often find a small cam or lack of offset. A burr should then be used to recreate the offset. In case of a pincer impingement gentle trimming of the acetabular rim might be indicated. Always check for any impingement in flexion, internal rotation and external rotation. The ligamentum teres is easy to examine. Simply place the joint in external rotation. It can be removed if necessary, although some authors suggest reconstruction (38).

The third stage is the capsule plasty (7, 39, 40) designed to restore tension to the capsule as with a Bankart shoulder repair (Fig. 21). Several techniques have been described, and there is no doubt that it works relatively well for instabilities where the bone is only a minor contributing factor. Patients are ordered to avoid full weight bearing for a month, and especially to avoid excessive extension of the hip. Personally, I make them wear a wedge insole for the operated leg for 35 days to encourage recovery. With these hips, it makes no sense not to repair the capsule, due to reports of recurring postoperative dislocations after arthroscopy (41, 42).

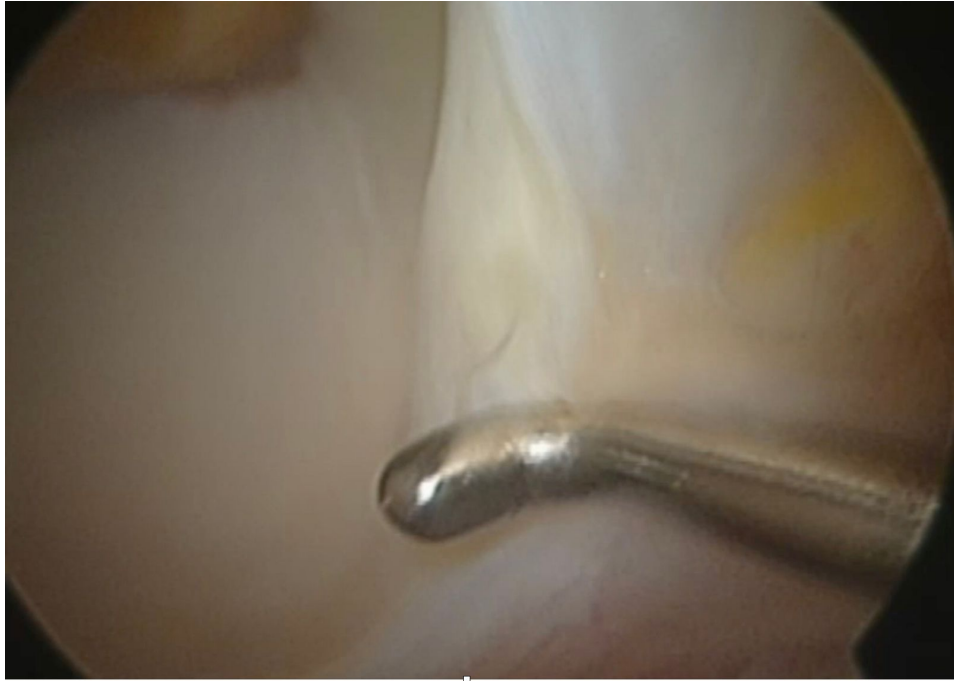

Figure 21: Fairly typical arthroscopy image of an unstable hip. There is a 5–10 mm wide band of chondromalacia at the acetabulum. This is the cause of the snapping symptoms by some patients.

Bony correction osteotomies

If bone defects are a major contributing factor, a corrective osteotomy should be considered (43-45).

There are two possible procedures for the femur: coxa valga correction, or derotation osteotomy for cases of severe excessive femoral neck antetorsion. However, a bad reputation means these are not common procedures. Recovery takes a long time, despite over the past decade having developed a minimally invasive technique that has halved the post-operative period and leaves only minimal scarring (46).

Bone surgery usually targets the acetabulum and there are two options. The classic shelf operation (47), which is no longer popular because of its highly random outcomes and the inability of combining it with an intra-articular procedure. The periacetabular osteotomy (PAO) described by Rheinhold Ganz and Jeff Mast in the 1980s (48) has become the gold standard. It is a very powerful operation because it can correct the entire acetabular anatomy and if needed easily open the joint and repair labrum defects (Fig. 22). It can correct all types of acetabular orientation defects, such as anteversion, deficient lateral coverage and retroversion (49).

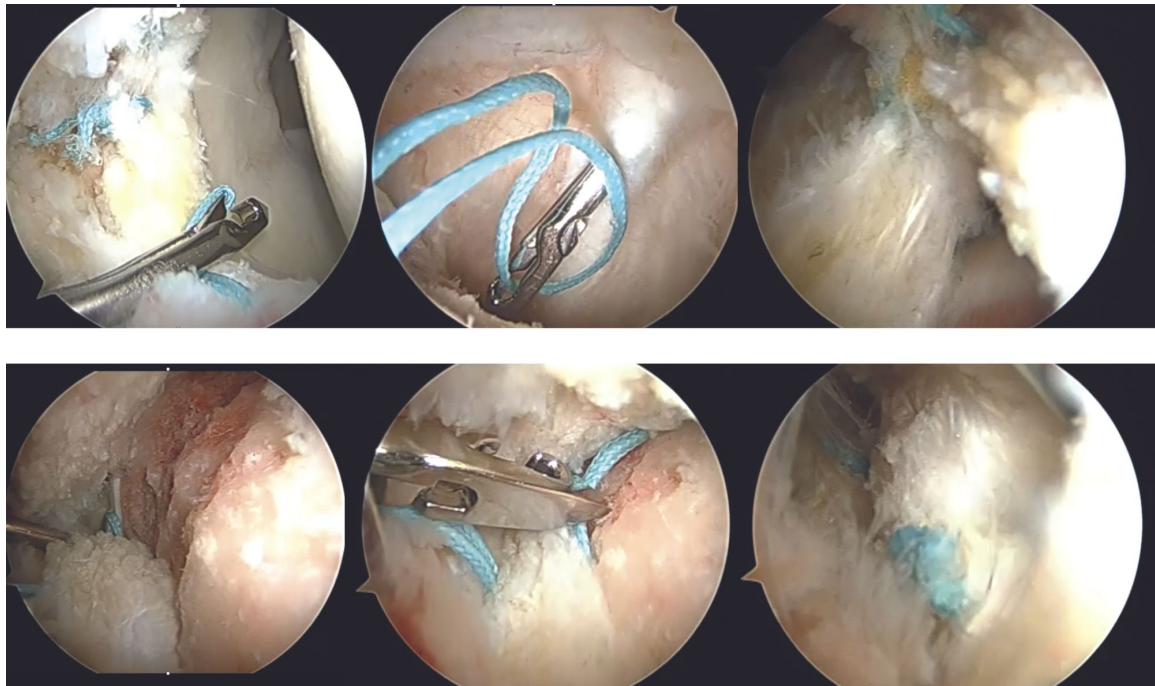


Figure 22: Capsule plasty. With a vertical opening parallel to the capsule fibres, 2–3 stitches will usually suffice for an effective capsule plasty. In some cases, an anchor can be placed just above the labrum to ensure very good closure down to the acetabulum. Traction is usually used to open the joint and make the upper stitches. The hip is then flexed to allow the thread to pass through the zona orbicularis. Two or three fairly large stitches are enough for a successful plasty. The joint should be closed and the knots tightened with the hip in flexion.

For the past decade or so, it has been performed using a more minimally invasive procedure with less soft tissue trauma, earlier rehab and virtually invisible scar measuring less than 7 cm in the groin fold with excellent clinical outcome (50-52).

After the surgery, the patient is able to fully weight bearing after three weeks, and it is no longer unusual to see patients fully recovered in less than two months. Not even arthroscopy is faster. The only drawback is that because it is not widely used in many countries, many surgeons are deterred by the learning curve. However, once mastered, it offers a solution to nearly all instabilities of the hip with bony deformities. In 25 years of practice, I have gone from performing operations that take four hours with a complicated recovery period, to an operating time of just one hour and early weight-bearing. The long-term results of PAO are well-documented and are highly promising (53-55).

Obviously, there is no way of modifying the genetic make-up of patients with a connective tissue disorder, so you have to work with the materials available. Depending on the anatomy, the options are either a bone procedure or a capsule plasty, or sometimes both. However, the risk that a capsule plasty will fail is much higher than in a patient without such a condition.

If the cartilage is in poor condition already and joint preserving surgery no longer would make sense, modern total hip arthroplasty remains a good solution for these patients. Since the risk of postoperative dislocation is higher in this patient group the surgery should be combined with measures to protect the capsule and muscles. We view these patients as an excellent indication for a minimally-invasive anterior approach without capsule release (36, 56).

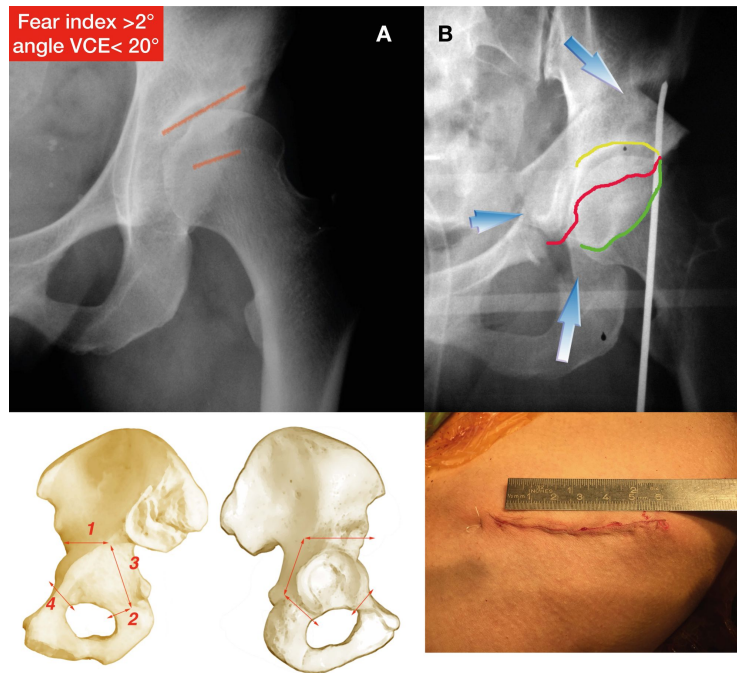


Figure 23: Minimally-invasive periacetabular osteotomy (PAO). Typical dysplastic hip with instability before and after PAO. Osteotomies of the iliac bone around the acetabulum, without affecting the continuity or structure of the posterior wall, allows fully correction of the acetabular version and lateral coverage. Any additional intraarticular pathologies might be addressed by open arthrotomy or arthroscopy.

CONCLUSION

Hip pain plus ‘normal’ x-rays does not always mean femoroacetabular impingement. It is about time we began recognizing and diagnosing microinstability of the hip. It is quite common to see young patients with all the clinical and radiological signs who have suffered disabling pain for many years. In some cases, it is no longer just a matter of being unable to do sports, but of discomfort during even simple tasks of daily living.

A good history-taking and standardized physical examinations are essential. The benefits of basic x-rays should be stressed. If CT scans or MRI are required, then they are best performed with intra-articular contrast injection. Conservative treatment is still the first treatment choice. It should aim to adopt live style, improve muscle symmetry, strength and proprioception. Nevertheless cases after failed conservative management clearly need to be referred to a surgeon. Arthroscopy is particularly appropriate if there is damage to the soft tissues, capsule or labrum. Minimally-invasive techniques for underlying bone defects are gradually replacing traditional procedures.

REFERENCES

1. **Beck M, Leunig M, Clarke E, Ganz R.** Femoroacetabular impingement as a factor in the development of nonunion of the femoral neck: a report of three cases. *J Orthop Trauma.* 2004;18(7):425-30.
2. **Ganz R, Parvizi J, Beck M, Leunig M, Notzli H, Siebenrock KA.** Femoroacetabular impingement: a cause for osteoarthritis of the hip. *Clin Orthop Relat Res.* 2003(417):112-20.
3. **Siebenrock KA, Gautier E, Woo AK, Ganz R.** Surgical dislocation of the femoral head for joint debridement and accurate reduction of fractures of the acetabulum. *J Orthop Trauma.* 2002;16(8):543-52.
4. **Gedouin JE, May O, Bonin N, Nogier A, Boyer T, Sadri H, et al.** Assessment of arthroscopic management of femoroacetabular impingement. A prospective multicenter study. *Orthop Traumatol Surg Res.* 2010;96(8 Suppl):S59-67.
5. **Ayeni OR, Larson CM, Bonin N, Safran MR.** Editorial: is the hip really a stable joint? *Knee Surg Sports Traumatol Arthrosc.* 2017;25(1):1-2.
6. **Safran MR.** Microinstability of the Hip-Gaining Acceptance. *J Am Acad Orthop Surg.* 2019;27(1):12-22.
7. **Domb BG, Philippon MJ, Giordano BD.** Arthroscopic capsulotomy, capsular repair, and capsular plication of the hip: relation to atraumatic instability. *Arthroscopy.* 2013;29(1):162-73.
8. **Lequesne M, de S.** [False profile of the pelvis. A new radiographic incidence for the study of the hip. Its use in dysplasias and different coxopathies]. *Rev Rhum Mal Osteoartic.* 1961;28:643-52.
9. **Jacobsen S, Sonne-Holm S, Soballe K, Gebuhr P, Lund B.** Hip dysplasia and osteoarthritis: a survey of 4151 subjects from the Osteoarthritis Substudy of the Copenhagen City Heart Study. *Acta Orthop.* 2005;76(2):149-58.
10. **Yeung M, Memon M, Simunovic N, Belzile E, Philippon MJ, Ayeni OR.** Gross Instability After Hip Arthroscopy: An Analysis of Case Reports Evaluating Surgical and Patient Factors. *Arthroscopy.* 2016;32(6):1196-204 e1.
11. **Kurz AZ, Memon M, Williams D, Ayeni OR.** Anterior Capsule Reconstruction of the Native Hip: A Technique Guide. *Arthrosc Tech.* 2019;8(10):e1247-e53.
12. **Larson CM, Stone RM, Grossi EF, Giveans MR, Cornelsen GD.** Ehlers-Danlos Syndrome: Arthroscopic Management for Extreme Soft-Tissue Hip Instability. *Arthroscopy.* 2015;31(12):2287-94.
13. **Ferguson SJ, Bryant JT, Ganz R, Ito K.** An in vitro investigation of the acetabular labral seal in hip joint mechanics. *J Biomech.* 2003;36(2):171-8.
14. **Ferguson SJ, Bryant JT, Ganz R, Ito K.** The acetabular labrum seal: a poroelastic finite element model. *Clin Biomech (Bristol, Avon).* 2000;15(6):463-8.
15. **Shu B, Safran MR.** Hip instability: anatomic and clinical considerations of traumatic and atraumatic instability. *Clin Sports Med.* 2011;30(2):349-67.
16. **van Arkel RJ, Amis AA, Cobb JP, Jeffers JR.** The capsular ligaments provide more hip rotational restraint than the acetabular labrum and the ligamentum teres : an experimental study. *Bone Joint J.* 2015;97-B(4):484-91.
17. **Martin HD, Savage A, Braly BA, Palmer IJ, Beall DP, Kelly B.** The function of the hip capsular ligaments: a quantitative report. *Arthroscopy.* 2008;24(2):188-95.
18. **Kolo FC, Charbonnier C, Pfirrmann CW, Duc SR, Lubbeke A, Duthon VB, et al.** Extreme hip motion in professional ballet dancers: dynamic and morphological evaluation based on magnetic resonance imaging. *Skeletal Radiol.* 2013;42(5):689-98.

19. **Mitchell RJ, Gerrie BJ, McCulloch PC, Murphy AJ, Varner KE, Lintner DM, et al.** Radiographic Evidence of Hip Microinstability in Elite Ballet. *Arthroscopy*. 2016;32(6):1038-44 e1.
20. **Haefeli PC, Steppacher SD, Babst D, Siebenrock KA, Tannast M.** An increased iliocapsularis-to-rectus-femoris ratio is suggestive for instability in borderline hips. *Clin Orthop Relat Res*. 2015;473(12):3725-34.
21. **Canham CD, Yen YM, Giordano BD.** Does Femoroacetabular Impingement Cause Hip Instability? A Systematic Review. *Arthroscopy*. 2016;32(1):203-8.
22. **Byrd JW.** Editorial Commentary: Iatrogenic Instability of the Hip: A Perfect Storm. *Arthroscopy*. 2016;32(6):1205-6.
23. **Henle P, Tannast M, Siebenrock KA.** [Imaging in developmental dysplasia of the hip]. *Orthopade*. 2008;37(6):525-31.
24. **Tannast M, Hanke MS, Zheng G, Steppacher SD, Siebenrock KA.** What are the radiographic reference values for acetabular under- and overcoverage? *Clin Orthop Relat Res*. 2015;473(4):1234-46.
25. **Tannast M, Siebenrock KA, Anderson SE.** [Femoroacetabular impingement: radiographic diagnosis-- what the radiologist should know]. *Radiologia*. 2008;50(4):271-84.
26. **Wyatt M, Weidner J, Pfluger D, Beck M.** The Femoro-Epiphyseal Acetabular Roof (FEAR) Index: A New Measurement Associated With Instability in Borderline Hip Dysplasia? *Clin Orthop Relat Res*. 2017;475(3):861-9.
27. **Truntzer JN, Hoppe DJ, Shapiro LM, Safran MR.** Can the FEAR Index Be Used to Predict Microinstability in Patients Undergoing Hip Arthroscopic Surgery? *Am J Sports Med*. 2019;47(13):3158-65.
28. **Packer JD, Cowan JB, Rebolledo BJ, Shibata KR, Riley GM, Finlay AK, et al.** The Cliff Sign: A New Radiographic Sign of Hip Instability. *Orthop J Sports Med*. 2018;6(11):2325967118807176.
29. **Notzli HP, Wyss TF, Stoecklin CH, Schmid MR, Treiber K, Hodler J.** The contour of the femoral head-neck junction as a predictor for the risk of anterior impingement. *J Bone Joint Surg Br*. 2002;84(4):556-60.
30. **Schmaranzer F, Lerch TD, Strasser U, Vavron P, Schmaranzer E, Tannast M.** Usefulness of MR Arthrography of the Hip with and without leg Traction in Detection of Intra-articular Bodies. *Acad Radiol*. 2019;26(9):e252-e9.
31. **McNeill W, Scott S.** Treatment of hip microinstability and gluteal tendinopathies involves movement control and exercise. *J Body Mov Ther*. 2016;20(3):588-94.
32. **Mook WR, Briggs KK, Philippon MJ.** Evidence and Approach for Management of Labral Deficiency: The Role for Labral Reconstruction. *Sports Med Arthrosc Rev*. 2015;23(4):205-12.
33. **Frank RM, Lee S, Bush-Joseph CA, Kelly BT, Salata MJ, Nho SJ.** Improved outcomes after hip arthroscopic surgery in patients undergoing T-capsulotomy with complete repair versus partial repair for femoroacetabular impingement: a comparative matched-pair analysis. *Am J Sports Med*. 2014;42(11):2634-42.
34. **Philippon MJ.** The role of arthroscopic thermal capsulorrhaphy in the hip. *Clin Sports Med*. 2001;20(4):817-29.
35. **Lodhia P, Gui C, Chandrasekaran S, Suarez-Ahedo C, Vemula SP, Domb BG.** Microfracture in the hip: a matched-control study with average 3-year follow-up. *Journal of hip preservation surgery*. 2015;2(4):417-27.
36. **Viamont-Guerra MR, Bonin N, May O, Le Viguelloux A, Saffarini M, Laude F.** Promising outcomes of hip mosaicplasty by minimally invasive anterior approach using osteochondral autografts from the ipsilateral femoral head. *Knee Surg Sports Traumatol Arthrosc*. 2019.
37. **Ayeni OR, Alradwan H, de Sa D, Philippon MJ.** The hip labrum reconstruction: indications and outcomes--a systematic review. *Knee Surg Sports Traumatol Arthrosc*. 2014;22(4):737-43.

38. **O'Donnell JM, Pritchard M, Salas AP, Singh PJ.** The ligamentum teres-its increasing importance. *Journal of hip preservation surgery.* 2014;1(1):3-11.
39. **Chandrasekaran S, Vemula SP, Martin TJ, Suarez-Ahedo C, Lodhia P, Domb BG.** Arthroscopic Technique of Capsular Plication for the Treatment of Hip Instability. *Arthrosc Tech.* 2015;4(2):e163-7.
40. **Ekhtiari S, de Sa D, Haldane CE, Simunovic N, Larson CM, Safran MR, et al.** Hip arthroscopic capsulotomy techniques and capsular management strategies: a systematic review. *Knee Surg Sports Traumatol Arthrosc.* 2017;25(1):9-23.
41. **Sheean AJ, Barrow AE, Burns TC, Schmitz MR.** Iatrogenic Hip Instability Treated With Periacetabular Osteotomy. *J Am Acad Orthop Surg.* 2017;25(8):594-9.
42. **Trousdale RT.** Recurrent anterior hip instability after a simple hip dislocation: a case report. *Clin Orthop Relat Res.* 2003(408):189-92.
43. **Ansari A, Jones S, Hashemi-Nejad A, Catterall A.** Varus proximal femoral osteotomy for hip dysplasia in adults. *Hip Int.* 2008;18(3):200-6.
44. **Buly RL, Sosa BR, Poultsides LA, Caldwell E, Rozbruch SR.** Femoral Derotation Osteotomy in Adults for Version Abnormalities. *J Am Acad Orthop Surg.* 2018;26(19):e416-e25.
45. **Hartigan DE, Perets I, Walsh JP, Domb BG.** Femoral Derotation Osteotomy Technique for Excessive Femoral Anteversion. *Arthrosc Tech.* 2017;6(4):e1405-e10.
46. **Frederic Laude AN, Roxana Viamont-Guerra.** L'ostéotomie fémorale a-t-elle encore une place dans la chirurgie conservatrice de la hanche ? *Maitrise Orthopédique.* 2019;285.
47. **Fawzy E, Mandellos G, De Steiger R, McLardy-Smith P, Benson MK, Murray D.** Is there a place for shelf acetabuloplasty in the management of adult acetabular dysplasia? A survivorship study. *J Bone Joint Surg Br.* 2005;87(9):1197-202.
48. **Ganz R, Klaue K, Vinh TS, Mast JW.** A new periacetabular osteotomy for the treatment of hip dysplasias. Technique and preliminary results. *Clin Orthop Relat Res.* 1988(232):26-36.
49. **Siebenrock KA, Steppacher SD, Tannast M, Buchler L.** Anteverting Periacetabular Osteotomy for Acetabular Retroversion. *JBJS Essent Surg Tech.* 2015;5(1):e1.
50. **Hussell JG, Mast JW, Mayo KA, Howie DW, Ganz R.** A comparison of different surgical approaches for the periacetabular osteotomy. *Clin Orthop Relat Res.* 1999(363):64-72.
51. **Troelsen A, Elmengaard B, Soballe K.** A new minimally invasive transsartorial approach for periacetabular osteotomy. *J Bone Joint Surg Am.* 2008;90(3):493-8.
52. **Matsuda DK, Martin HD, Parvizi J.** Endoscopy-Assisted Periacetabular Osteotomy. *Arthrosc Tech.* 2016;5(2):e275-80.
53. **Wells J, Millis M, Kim YJ, Bulat E, Miller P, Matheney T.** Survivorship of the Bernese Periacetabular Osteotomy: What Factors are Associated with Long-term Failure? *Clin Orthop Relat Res.* 2017;475(2):396-405.
54. **Hamai S, Kohno Y, Hara D, Shiimoto K, Akiyama M, Fukushi JI, et al.** Minimum 10-Year Clinical Outcomes After Periacetabular Osteotomy for Advanced Osteoarthritis Due to Hip Dysplasia. *Orthopedics.* 2018;41(5):300-5.
55. **Ziran N, Varcadipane J, Kadri O, Ussef N, Kanim L, Foster A, et al.** Ten- and 20-year Survivorship of the Hip After Periacetabular Osteotomy for Acetabular Dysplasia. *J Am Acad Orthop Surg.* 2019;27(7):247-55.
56. **Viamont-Guerra MR, Chen AF, Stirling P, Nover L, Guimaraes RP, Laude F.** The Direct Anterior Approach for Total Hip Arthroplasty for Severe Dysplasia (Crowe III and IV) Provides Satisfactory Medium to Long-Term Outcomes. *J Arthroplasty.* 2020.